



## Case Report

# Anaesthesia management of pregnant patient with uncorrected middle aortic syndrome (MAS) for caesarean section

Ninad Chodankar<sup>1,\*</sup>, Madhuri Kharwadkar<sup>1</sup>

<sup>1</sup>Dept. of Anaesthesia, Lilavati Hospital and Research Center, Mumbai, Maharashtra, India



### ARTICLE INFO

#### Article history:

Received 25-10-2020

Accepted 18-02-2021

Available online 10-09-2021

#### Keywords:

Middle

Aortic

Syndrome

Coarctation

Aorta

Caesarean

Section

### ABSTRACT

Middle aortic syndrome is a rare congenital disease which involves segmental or diffuse narrowing of the abdominal and/or distal descending thoracic aorta. It may remain largely undetected in childhood and can present itself as gestational hypertension during pregnancy. Upper extremity hypertension is difficult to control during pregnancy. Excessive blood pressure lowering may result in hypotension distal to the obstruction and uterine hypoperfusion.

It offers considerable challenge to Anaesthesiologist regarding choice of anaesthesia – Regional verses General Anaesthesia. Both having its own advantages and disadvantages in such patient.

We describe a 29 years, primigravida with Middle aortic syndrome, diagnosed during first trimester. Patient was admitted with severe hypertension in upper extremity at 39 weeks. Caesarean delivery was carried out under General Anaesthesia. During perioperative period, Intravenous Nitroglycerine and Labetalol were used to maintain hemodynamic stability. Patient was shifted to ICU on ventilator. She had uneventful course in ICU and recovery was good.

Pregnant Patient with uncorrected Middle aortic syndrome for Caesarean Section require suitable anaesthesia technique along with good blood pressure management leading to early recovery and reduction in complications.

This is an Open Access (OA) journal, and articles are distributed under the terms of the [Creative Commons Attribution-NonCommercial-ShareAlike 4.0 License](https://creativecommons.org/licenses/by-nc-sa/4.0/), which allows others to remix, tweak, and build upon the work non-commercially, as long as appropriate credit is given and the new creations are licensed under the identical terms.

For reprints contact: [reprint@ipinnovative.com](mailto:reprint@ipinnovative.com)

## 1. Introduction

Middle aortic syndrome (MAS) is a rare congenital disease which involves segmental or diffuse narrowing of the abdominal and/or distal descending thoracic aorta.<sup>1</sup> It presents in children and young adults and constitutes 0.5%–2% of all the cases of Coarctation of the aorta.<sup>2</sup> MAS or Coarctation of the aorta results in upper extremity hypertension, which may be difficult to control during pregnancy. Excessive blood pressure lowering in the upper extremities may result in hypotension distal to the obstruction leading to uterine hypoperfusion.<sup>3</sup>

MAS can predispose the patient to aortic dissection. Aortic rupture is the most common cause of death in pregnant women with coarctation. In view of these complications, elective caesarean section should be considered in patients with an unrepaired coarctation.<sup>4</sup>

Conducting such a case offers considerable challenge to Anaesthesiologist regarding choice– Regional verses General Anaesthesia. Both having its own advantages and disadvantages in such patients.

## 2. Case Report

Patient is 29 years, primigravida, detected to have the high Blood pressure reading for the first time during 1<sup>st</sup> trimester. She was otherwise asymptomatic with no prior

\* Corresponding author.

E-mail address: [ninad.chodankar@gmail.com](mailto:ninad.chodankar@gmail.com) (N. Chodankar).

medical check-ups, hence did not have Blood pressure checks done earlier. She was therefore evaluated in order to find the cause for high BP. On Echocardiography, she was diagnosed to have Middle aortic syndrome (MAS). She was started on tablet Nifedipine 60mg twice a day and tablet Labetalol 100mg three times a day, by cardiologist. She had otherwise uneventful antenatal visits with no other complications.

All Haematological and biochemical investigations were within normal limits. ECG was normal. Echocardiography showed LVEF 55%, mild PAH (PASP 40mmHg), Grade 1 Tricuspid Regurgitation. RVEF 50%. Descending thoracic and abdominal aorta was scanned with systolic and diastolic continuous flow with gradient of 70-80mmHg in abdominal aorta. Features suggestive of Middle aortic syndrome.

Patient received tablet Nifedipine 60mg twice a day and tablet Labetalol 100mg three times a day. She had otherwise normal antenatal period with no other complications.

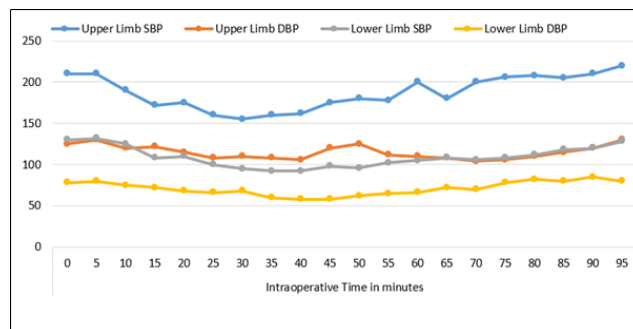
At 39 weeks, Patient was admitted for safe confinement. Pre-anaesthetic evaluation was done day prior to LSCS. She was asymptomatic, weighed 61kgs and had BP of 220/140mmHg in upper limbs. Patient was shifted to ICU. Started on intravenous Nitroglycerine and Labetalol infusion to reduce blood pressure. Right Radial artery and Left Dorsalis pedis artery were cannulated, under Local Anaesthesia, to obtain continuous BP monitoring. And posted next day for LSCS.

We decided to conduct the case under General Anaesthesia. Pre-medication in the form of intravenous ranitidine 50mg, intravenous metoclopramide 10mg along with antibiotic prophylaxis was given one hour prior to procedure. Intraoperatively continuous monitoring of following parameters was carried out: ECG, SPO<sub>2</sub>, two Invasive Blood Pressure (Right Radial artery and Left Dorsalis pedis artery), EtCO<sub>2</sub>, Gas analyser, Temperature.

Two 20G Intravenous access were obtained before procedure. Intravenous Nitroglycerine and Labetalol infusions were continued intraoperatively.

GA was Induced with 5mg/kg intravenous Thiopentone, titrated to effect and intravenous Succinyl choline 1mg/kg. RSI with cricoid pressure. Intravenous Lignocaine 1.5mg/kg was administered 1.5 min before laryngoscopy to attenuate pressor response. Patient was Intubated with 7 number Portex ET and ventilated to maintain normocarbia. Anaesthesia was maintained with Oxygen and Air with Sevoflurane to a MAC of 0.7-0.8. A live male baby was delivered weighing 2250 grams, with Apgar of 8 and 10 at birth and 10 minutes respectively. Intravenous Fentanyl 2mcg /kg was administered after delivery of the baby. Atracurium, was administered as a bolus to maintain muscle relaxation. After delivery intravenous oxytocin has to be given slowly in order to avoid sudden drop in blood pressure.

Intravenous Nitroglycerine and Labetalol infusion were used to maintain blood pressure intraoperatively. Infusion was adjusted to lower BP in upper limb, and at the same to keep MAP of more than 65mmHg and Systolic BP reading more than 90mmHg in Left Dorsalis pedis artery. Good Urine output was also used as an indicator of good distal perfusion. Maximum dose of Nitroglycerine during surgery was 6 mcg/kg/min and Labetalol was 0.8 mg/kg/hr.



**Fig. 1:** Intraoperative Blood pressure measurement. Blue line represent SBP and Orange line DBP in upper limb. Grey line represent SBP and yellow line DBP in lower limb. 0 minute marks entry of patient into operation theatre, 5 minutes point of induction

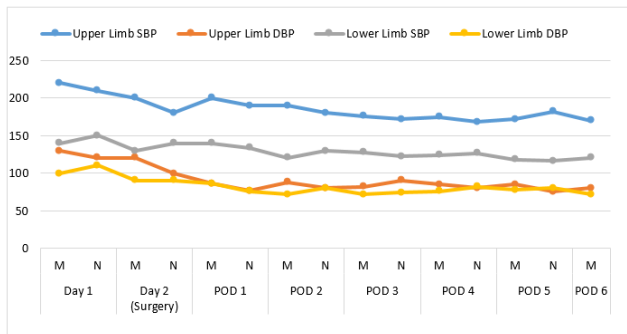
Surgery lasted for one hour. Intraoperatively 1200ml of IV crystalloids was administered. Total Urine output was 200ml and Blood loss was 400ml.

Intravenous Paracetamol 1 gram and Intravenous Diclofenac 75mg were given for post-operative analgesia. Local infiltration of 20ml of 0.25% Bupivacaine at the incision site was given by surgical team.

As per the plan, we decided to give a trial of reversal with IV Neostigmine 0.05mg/kg and IV Glycopyrrolate 0.01mg/kg. But the patient had poor respiratory efforts and Systolic invasive blood pressure in Right Radial artery started shooting to unacceptably high levels. Hence it was decided to electively ventilate the patient in ICU.

In ICU, oral anti-hypertensives (tablet Telmisartan 40mg twice a day, tablet Metoprolol 25mg once a day, tablet Spironolactone 50 mg once a day and tablet Torsemide 10 mg once a day) via NG tube was started on Post-operative day 1. Computed Tomography scan of Brain was done to rule out any neurological complications that could have arisen due to surges in BP. Patient was extubated on Post-operative day 2 after successful Spontaneous breath trial on the T-piece. Intravenous Nitroglycerine and Labetalol infusion were tapered and stopped after starting oral antihypertensives. Tablet Cilindipine 10mg twice a day was added. The Patient was shifted to ward on Post-operative day 3. Intravenous Paracetamol 1 gram three times a day and Intravenous Diclofenac 75mg twice a day were used for analgesia.

Patient had uneventful stay in the hospital and was discharged on Post-operative day 6 with tablet Telmisartan



**Fig. 2:** Blood pressure Monitoring In Hospital. Blue line represent SBP and Orange line DBP in upper limb. Grey line represent SBP and yellow line DBP in lower limb. M stands for BP recorded in Morning at 8am and N stands for BP recored at night at 8pm

40mg twice a day, tablet Cilindipine 10mg twice a day, and tablet Metoprolol 25mg once a day.

### 3. Discussion

Middle aortic syndrome (MAS) is a rare congenital disease which involves segmental or diffuse narrowing of the abdominal and/or distal descending thoracic aorta.<sup>1</sup> It presents in children and young adults and constitutes 0.5%–2% of all the cases of Coarctation of the aorta.<sup>2</sup> The incidence of this disease in the pregnant population has been steadily decreasing because of early detection in childhood and corrective procedures. The maternal mortality for patients with uncorrected coarctation of the aorta is 3 to 8% and fetal mortality is as high as 20%.

MAS or Coarctation of the aorta results in upper extremity hypertension, which may be difficult to control during pregnancy.<sup>3</sup> The physiological changes during pregnancy including increase in circulating blood volume contribute to hypertension and predispose the patient to complications such as dissection of aorta. The risk of complications like aortic dissection or congestive cardiac failure increases in late pregnancy or within 6 weeks postpartum due to haemodynamic changes.<sup>5</sup>

Excessive blood pressure lowering in the upper extremities may result in hypotension distal to the obstruction and uterine hypoperfusion.<sup>3</sup> MAS can predispose patient to aortic dissection. Aortic rupture is the most common cause of death in pregnant women with coarctation. In view of these complications, elective Caesarean section should be considered in patients with an unrepaired coarctation.<sup>4</sup> European Society of Cardiology guidelines also recommend Spontaneous vaginal delivery with use of epidural anaesthesia.<sup>6</sup>

For patients requiring caesarean section, there is difference of opinion regarding choice of anaesthesia – Regional Anaesthesia vs General Anaesthesia, choice depending upon patient condition and setup available.

Regional anaesthesia, especially spinal anaesthesia can cause sudden drop in blood pressure which can affect distal perfusion. Epidural anaesthesia does not cause sudden drop in blood pressure, if given in graded manner.<sup>7</sup> Any drop in blood pressure will affect the distal perfusion compromising renal and uteroplacental flow. There are multiple reports of Regional anaesthesia being used, either epidural alone or combination with spinal for patient with uncorrected CoA.<sup>8–11</sup>

Many anaesthesiologist do not prefer GA due to occurrence of haemodynamic changes during laryngoscopy, intubation and incision. These haemodynamic changes are also can occur during extubation. There is increased risk of aortic rupture, dissection or cerebral haemorrhage at these times.

Tadwalkar<sup>8</sup> reported use of graded epidural anaesthesia only for elective Caesarean section in a case of unrepaired coarctation of the aorta. Bourgeade<sup>9</sup> reported a woman with coarctation of aorta for caesarean delivery under spinal-epidural anaesthesia. They observed occurrence of arterial hypotension despite the use of a titrated regional anaesthesia. Ruys et al<sup>10</sup> successfully performed elective caesarean section under regional anaesthesia in a patient with Native Aortic Coarctation and Aneurysm. Walker E<sup>11</sup> reported 2 cases with were successfully done under incremental regional anaesthetic technique.

In our patient, we had upper and lower BP gradient of almost 80mmHg via Echocardiography. Administration of regional anaesthesia could have led to reduction in preload and afterload, especially distal to CoA with resultant renal and placental insufficiency. Even Epidural anaesthesia alone can cause significant drop in BP. Also our patient already had uncontrolled BP despite of oral medication and had required ICU admission with IV Nitroglycerine and Labetolol infusions preoperatively to acheive optimal BP control. In spite of all these measures, Upper limb BP remained high and BP gradient was 80mmHg. So we decided to go for General Anaesthesia with two arterial lines. Our case is similar to a case report by Goel et al.<sup>12</sup> They also reported gradient of more than 100mmHg and preferred General anaesthesia for their case.

We had Nitroglycerine and Labetalol infusion throughout the procedure and we used Lignocaine bolus to attenuate pressor response to laryngoscopy and intubation. Infusion was adjusted to lower BP in upper limb, and at the same to keep MAP of more than 65mmHg and Systolic BP reading more than 90mmHg in Left Dorsalis pedis artery. Good Urine output was also used as an indicator of good distal perfusion.

Nitroglycerine and Labetalol infusions have been proven effective in past.<sup>13,14</sup> We were able to avoid any fluctuations and any sudden increase in BP with the use of infusion.

Intraoperatively care has to be taken to avoid sudden decrease in BP by giving graded bolus of Fentanyl or

adjusting anaesthetic agent. Even after delivery intravenous oxytocin has to be given slowly in order to avoid sudden drop in blood pressure.

In our case, we were unable to extubate the patient on table due to persistent high BP and poor respiratory efforts. We decided to shift the patient to ICU. Sedation was maintained and oral antihypertensives were started via NG tube. After achieving good control of BP with oral drugs patient was weaned gradually of intravenous infusions. CT Brain was done to rule out any neurological complications that could have arisen due to surges in BP. We were able to extubate the patient on Post-operative day 2 after starting oral antihypertensives and gradually stopping Nitroglycerine and Labetalol infusions.

#### 4. Conclusion

Our experience in this case, leads us to conclude that General anaesthesia is appropriate in patient with MAS or Coarctation of the aorta with high BP gradient between upper and lower extremity; and also in patients with severely uncontrolled BP. As cited by various studies, regional anaesthesia can also been used successfully in specific patients.

Multidisciplinary approach with good team work between Obstetrician, Cardiologist, Anaesthesiologist and Intensivist is essential for relief of symptoms. For anaesthesiologist, it is essential to choose appropriate anaesthesia for good outcome in patient with MAS. Also, it is vital to be aware of various complications that can occur in such patients and manage them, leading to safe confinement and early recovery.

#### 5. Source of Funding

None.

#### 6. Conflict of Interest


The author declares no conflict of interest.

#### References

1. Rumman RK, Nickel C, Matsuda-Abedini M, Lorenzo AJ, Langlois V, Radhakrishnan S, et al. Disease Beyond the Arch: A Systematic

- Review of Middle Aortic Syndrome in Childhood. *Am J Hypertens.* 2015;28(7):833–46.
2. Cohen JR, Birnbaum E. Coarctation of the abdominal aorta. *J Vasc Surg.* 1988;8(2):160–4.
3. Beauchesne LM, Connolly HM, Ammash NM, Warnes CA. Coarctation of the aorta: outcome of pregnancy. *J Am Coll Cardiol.* 2001;38(6):1728–33.
4. Harris IS. Management of Pregnancy in Patients with Congenital Heart Disease. *Prog Cardiovasc Dis.* 2011;53(4):305–11.
5. Connolly HM. Pregnancy in women with coarctation of the thoracic aorta. *ACC Curr J Rev.* 1997;55:6–7.
6. Warnes CA, Williams RG, Bashore TM, Child JS, Connolly HM, Dearani JA. ESC Guidelines on the management of cardiovascular diseases during pregnancy. *Eur Heart J.* 2011;32:3147–97.
7. Bengali R, Patil T. Coarctation of Aorta and Takayasu Arteritis for LSCS: Anaesthesia Management. *J Evol Med Sci.* 2015;82(4):14427–31.
8. Tadwalkar G, Ghodekar O. Coarctation of the Aorta in Caesarean section: An Anaesthetic challenge. *Annals of International Medical and Dental Research.* 2017;3(6):5–7.
9. Bourgeade F, Malinovsky JM. Anaesthetic management for caesarean section in a parturient with uncorrected coarctation of the aorta. *Ann Fr Anesth Reanim.* 2010;29:642–4.
10. Ruys TPE, Bekkers JA, Duvekot JJ, Roos-Hesselink JW. A Pregnant Patient with Native Aortic Coarctation and Aneurysm. *Aorta.* 2014;2:110–2.
11. Walker E, Mallins AF. Anesthetic management of aortic coarctation pregnancy. *Int J Obstet Anesth.* 2004;13:266–70.
12. Goel N, Sen I, Mandal B, Prassana V. Anaesthetic Management of Caesarean Section in a Patient with Severe Uncorrected Coarctation of Aorta: A Case Report and Literature Review. *J Obstet Anaesth Crit Care.* 2018;8:54–7.
13. Longmire S, Leduc L, Jones MM, Hawkins JL, Joyce TH, Cotton DB. The hemodynamic effects of intubation during nitroglycerin infusion in severe preeclampsia. *Am J Obstet Gynecol.* 1991;164:551–6.
14. Ramanathan J, Sibai BM, Mabie WC, Chauhan D, Ruiz AG. The use of labetalol for attenuation of the hypertensive response to endotracheal intubation. *Am J Obstet Gynecol.* 1988;159(3):650–4. doi:0.1016/s0002-9378(88)80027-9.

#### Author biography

**Ninad Chodankar**, Clinical Associate  <https://orcid.org/0000-0003-3609-9017>

**Madhuri Kharwadkar**, Consultant

**Cite this article:** Chodankar N, Kharwadkar M. Anaesthesia management of pregnant patient with uncorrected middle aortic syndrome (MAS) for caesarean section. *Indian J Clin Anaesth* 2021;8(3):483–486.